

# Spontaneous Middle Cerebral Arterial Dissection Presented with Limb Shaking

Yi-Chien Liu<sup>1</sup>, Chih-Ping Chung<sup>2</sup>, Ping-Keung Yip<sup>1,3</sup>, and Vinchi Wang<sup>1,3</sup>

**Abstract-** Middle cerebral artery dissection (MCAD) is a rare cause for ischemic stroke and is often associated with headache and hemispheric symptoms. In the present report, limb shaking is found to be a major symptom of spontaneous MCAD in a young male. The diagnosis of MCAD is based on the intramural hematoma directly visualized in MR T2-weighted images and supported by serial evolution of transcranial doppler sonography. This presentation suggests that limb shaking can be a symptom of severe intracranial carotid occlusive disease.

**Key Words:** Limb shaking, Middle cerebral artery dissection, Carotid artery dissection, Intracranial occlusive disease

*Acta Neurol Taiwan 2009;18:26-29*

## INTRODUCTION

Arterial dissections are the second most common vascular lesion affecting the cervical carotid and vertebral arteries, after atherosclerosis<sup>(1)</sup>. But arterial dissection of intracranial internal carotid artery (ICA) and their branch vessels is rare. Headache and hemispheric symptoms are considered to be typical presentations in these intracranial carotid occlusive diseases. In this report, we provide evidence to suggest that limb shaking can also be one of the initial manifestations. The magnetic resonance imaging techniques are replacing conventional angiography in the diagnosis of dissections of the carotid and vertebral arteries<sup>(1-3)</sup>. We also confirmed

the diagnosis of middle cerebral artery dissection (MCAD) of this patient by T2-weighted images with direct visualization of an intramural hematoma and severe irregular stenosis in the magnetic resonance angiography (MRA).

## CASE REPORT

A 26-year-old man complained having off-and-on headaches and the development of intermittent “jerky” movement of the right upper limb 2 weeks before admission. The jerks involved the arm alone or concurrently with the leg. It usually involved distal joint alone and he had never falls due to the involuntary movement.

From the <sup>1</sup>Neurological Center, Cardinal Tien Hospital, Taipei, Taiwan; <sup>2</sup>The Neurological Institute, Taipei Veterans General Hospital, Taipei, Taiwan; <sup>3</sup>School of Medicine, Fu-Jen Catholic University, Taipei, Taiwan.

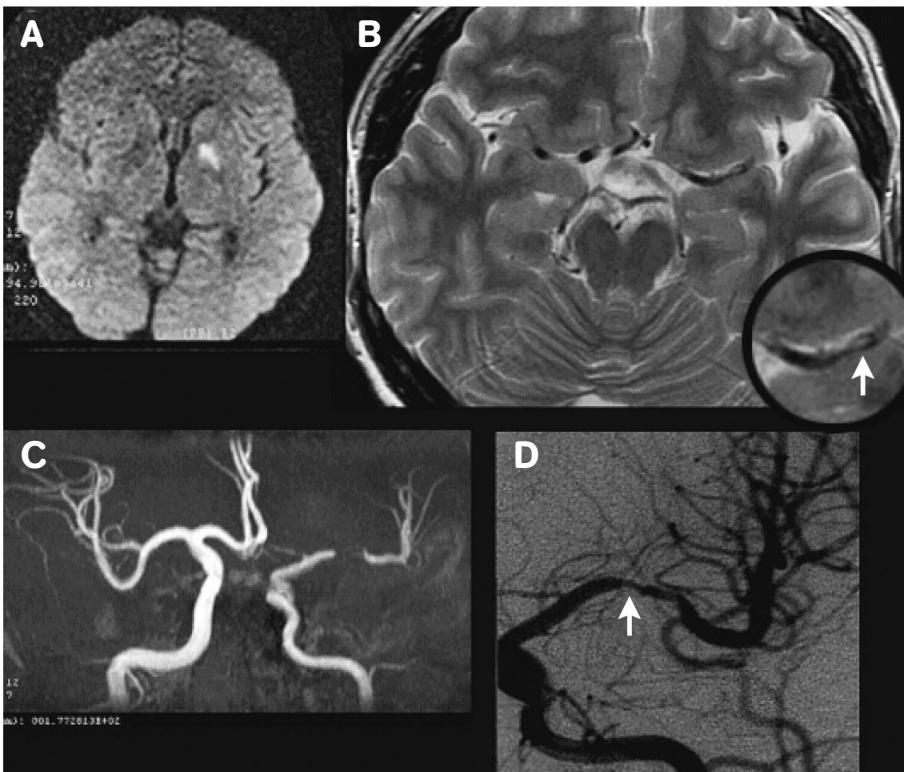
Received May 28, 2008. Revised June 18, 2008.

Accepted July 21, 2008.

Reprint requests and correspondence to: Vinchi Wang, MD, PhD. Neurological Center, Cardinal Tien Hospital, No. 362, Chung-Cheng Road, Hsintien, Taipei 231, Taiwan.  
E-mail: vwneur@yahoo.com.tw

The movements occurred briefly for a few seconds, and were involuntary. The movements were stereotypic but happened to irregular extent during the day. Intentional motions, such as standing up from a chair or reaching for a cup of tea with his hand, didn't induce the jerks. The frequency was 5-6 times per day but increased up to several times per hour before admission. Rest or lying position attenuated the frequency of the attacks. His consciousness was clear during the attacks. He didn't have any aura before the involuntary movements or post-ictal confusion or fatigue. He denied histories of hypertension, diabetes mellitus, migraine, head trauma, or vigorous neck movement. He also denied having any prior exposure to illicit drugs. He smoked one pack of cigarettes per day since teenage. Neurological examination did not show any focal neurological deficits except mild difficulty in word finding. The results of other laboratory tests and echocardiographic evaluations were unremarkable. Focal seizures were suspected at first, but the interictal EEG showed no epileptiform discharges. His

symptoms subsided transiently after administration of phenytoin. Lumbar puncture was performed due to suspicion of temporal lobe encephalitis, which revealed absence of cells in the CSF and negative PCR results for HSV-1. No orthostatic hypotension occurred during admission. The diffusion-weighted images of brain MRI, which were taken 2 weeks after onset of the symptoms, showed hyperintensity at the left globus pallidus (Fig. A). The T2-weighted images showed a suspicious intramural hematoma (Fig. B). MR angiography revealed absence of signal in the mid-portion of middle cerebral artery (MCA) (Fig. C). Digital subtraction cerebral angiography 4 weeks after onset showed segmental stenosis about 50-60% of mid-portion of the left MCA (Fig. D). His symptoms gradually improved after the use of aspirin (100mg per day). We applied transcranial color-coded sonography during the follow-up period, which revealed gradual improvement of the left MCA flow (Table). At the one-year follow-up, his attacks vanished completely.



**Figure.** (A) Diffusion-weighted images of brain MRI revealed high signal intensity lesions at left globus pallidus. (B) T2-weighted image showed a suspicious intramural hematoma (the arrow). (C) Magnetic resonance angiogram (MRA) showed severe irregular stenosis of the left middle cerebral artery. (D) Digital subtraction cerebral angiography showed segmental stenosis about 50-60% of mid-portion of left middle cerebral artery.

**Table.** Transcranial Doppler findings of the middle cerebral arteries

	Left MCA (Depth: 54-60 mm)		Right MCA (Depth: 54-60 mm)	
	BFV (S/D)	PI	BFV (S/D)	PI
Two weeks after onset	518 / 247	0.85	102 / 45	0.9
One month after onset	305 / 181	0.55	100 / 43	0.9
Seven months after onset	193 / 97	0.74	136 / 63	0.83

MCA: middle cerebral artery; BFV: blood flow velocity; S/D: systolic /diastolic, in cm/sec; PI: pulsatility index.

## DISCUSSION

Arterial dissections are the second most common vascular lesion affecting the cervical carotid and vertebral arteries, after atherosclerosis<sup>(1)</sup>. Dissections are usually categorized as traumatic (blunt injury or knife and bullet wounds) or spontaneous. The arterial dissection of intracranial internal carotid artery (ICA) and associated branch vessels is rare, particularly when compared with dissection of the cervical ICA<sup>(4)</sup>. This discrepancy may be explained by the greater mobility of the extracranial internal carotid and vertebral arteries and the potential for them to be injured by contact with bony structures, such as the cervical vertebrae or the styloid process. MCAD could be classified according to the site of dissection; i.e., either extended dissection from the distal portion of ICA or isolated MCAD<sup>(3)</sup>. Isolated MCAD is an even more rare cause of arterial dissection. The etiologies, clinical manifestations, natural history and prognosis of isolated MCAD remain poorly understood. But previous reports showed a more fluctuating course in patients with isolated MCAD<sup>(3)</sup>.

Localized warning signs are common before cerebral ischemia occurs in cerebral arterial dissection. Typical symptoms include pain on one side of the head, face or neck accompanied by a partial Horner's syndrome (oculosympathetic palsy) and followed by cerebral or retinal ischemia hours or days later. The onset of headache is usually gradual, but it may be an instantaneous, excruciating or explosive headache that mimics a subarachnoid hemorrhage. The location of headache is the same side of dissected vessel. Oculosympathetic palsy, consisting of miosis and ptosis, has long been recognized as a typical manifestation of carotid-artery dissection, but it is found

among less than half of patients. Transient ischemic attacks (TIA) or transient monocular blindness could also precede the ischemic stroke in patients with a spontaneous dissection of the carotid artery<sup>(1)</sup>. Only one fifth of patients have an ischemic stroke without any warning signs<sup>(5)</sup>. Among all the warning signs, limb shaking syndrome is rarely reported<sup>(6)</sup>.

A shaking limb episode has been described as "a brief, involuntary, coarse, irregular waving movement or tremble" involving arm-hand alone or arm-hand and leg together<sup>(7)</sup>. Limb shaking (LS) usually occurs in patients with severe extracranial carotid occlusive disease, and is often mistaken for a focal seizure attack<sup>(7-9)</sup>. The attacks are often evoked by postural change and the symptoms are sometimes attenuated after sitting or lying down<sup>(7,8,10)</sup>. Hemodynamic failure is attributed to the transient ischemic attacks with LS<sup>(11)</sup>. The hyperkinetic movement in limb shaking TIA may represent either the loss of inhibition or a state of primary hyperexcitability. Bilateral clonic jerks happened during syncope may be caused by subcortical release phenomenon resulting from diffuse cortical hypoxia<sup>(8)</sup>. It has been suggested that limb shaking TIA is a focal manifestation of the same process<sup>(8)</sup>. LS induced by anterior cerebral artery or middle cerebral artery stenosis has also been reported<sup>(12,13)</sup>, which indicates that LS is not an exclusive feature of extracranial carotid occlusive disease, but also attributes to intracranial artery disease. In previous reports<sup>(12,13)</sup>, LS could involve lower leg alone or at times, the arm. Their cases are different from ours because different ischemic areas are involved.

Conventional angiography has long been the gold standard in the diagnosis of arterial dissections. However, pathognomonic features of dissection, such as

an intimal flap or a double lumen, are detected in less than 10 percent of dissected extracranial arteries<sup>(1)</sup>. Segmental stenosis of the involved vessel segment is the most common angiographic finding in previous reported cases<sup>(3)</sup>. Nowadays, magnetic resonance imaging techniques are replacing conventional angiography in the diagnosis of dissections of the carotid and vertebral arteries. It is superior to the angiography in the diagnosis of dissection without associated luminal abnormalities or in cases resulting in nonspecific occlusions. Previous reports about MCAD suggest that axial source three-dimensional time-of-flight (3-D TOF) MRA images are a sensitive alternative of noninvasive procedure<sup>(4)</sup>. In our case, the MCAD is also confirmed by T2-weighted images with direct visualization of an intramural hematoma. In addition to anatomical imaging studies, serial follow-up examinations by transcranial doppler sonography revealed a resolving MCA stenosis which is compatible to the natural course of vessel dissection<sup>(14)</sup>.

As far as we know, LS caused by MCAD was very rarely reported before in the literature. In our case, the fluctuating course of headache at young age is compatible with prior reports on patients with isolated MCAD<sup>(3)</sup>. Patients with LS are at a high risk of stroke<sup>(11)</sup> and it is important to recognize episodic limb shaking as potential cerebral ischemic events.

## REFERENCES

1. Schievink WI. Spontaneous dissection of the carotid and vertebral arteries. *N Engl J Med* 2001;344:898-906.
2. Lin CH, Jeng JS, Yip PK. Middle cerebral artery dissection: differences between isolated and extended dissections of internal carotid artery. *J Neurol Sci* 2005;235:37-44.
3. Lee JS, Bang OY, Lee PH, et al. Two case of spontaneous middle cerebral arterial dissection causing ischemic stroke. *J Neurol Sci* 2006;205:162-6.
4. Schievink WI, Mokri B, Piepgras DG. Spontaneous dissections of cervicocephalic arteries in childhood and adolescence. *Neurology* 1994;44:1607-12.
5. Biousse V, D'Anglejan-Chatillon J, Touboul PJ, et al. Time course of symptoms in extracranial carotid artery dissections. A series of 80 patients. *Stroke* 1995;26:235-9.
6. Vila N, Chamorro A. Limb shaking syndrome triggered by severe anemia in a patient with dissection of the internal carotid artery. *Med Clin (Barc)* 1998;110:559.
7. Baquis GD, Pessin MS, Scott RM. Limb shaking: a carotid TIA. *Stroke* 1985;16:444-8.
8. Yanagihara T, Piepgras DG, Klass DW. Repetitive involuntary movement associated with episodic cerebral ischemia. *Ann Neurol* 1985;18:244-50.
9. Ali S, Khan MA, Khealani B. Limb-shaking transient ischemic attacks: case report and review of literature. *BMC Neurol* 2006;6:5.
10. Zaidat OO, Werz MA, Landis DM, et al. Orthostatic limb shaking from carotid hypoperfusion. *Neurology* 1999;53:650-1.
11. Baumgartner RW, Baumgartner I. Vasomotor reactivity is exhausted in transient ischaemic attacks with limb shaking. *J Neurol Neurosurg Psychiatry* 1998;65:561-4.
12. Han SW, Kim SH, Kim JK, et al. Hemodynamic changes in limb shaking TIA associated with anterior cerebral artery stenosis. *Neurology* 2004;63:1519-21.
13. Jiang WJ, Gao F, Du B, et al. Limb-shaking transient ischemic attack induced by middle cerebral artery stenosis. *Cerebrovasc Dis* 2006;21:421-2.
14. Lu CJ, Sun Y, Jeng JS, et al. Imaging in the diagnosis and follow-up evaluation of vertebral artery dissection. *J Ultrasound Med* 2000;19:263-70.